



Research Article

Efficacy of bilateral ultrasonography-guided transversus abdominis plane block after laparoscopic sleeve gastrectomy: Prospective, randomized, controlled study

Selcuk Alver ^{a,*} , Tarik Umutoglu ^b , Ismail Sumer ^c , Senniye Ulgen Zengin ^d ,
Ufuk Topuz ^e , Mefkur Bakan ^e , Kadir Idin ^a , Suleyman Bozkurt ^c , Ziya Salihoglu ^f 

^a Department of Anesthesiology and Reanimation, Medipol University, Faculty of Medicine, İstanbul, Türkiye

^b Department of Anesthesiology and Reanimation, İstanbul Health and Technology University, Faculty of Medicine, İstanbul, Türkiye

^c Department of Anesthesiology and Reanimation, Bezmialem Vakıf University, Faculty of Medicine, İstanbul, Türkiye

^d Department of Anesthesiology and Reanimation, Marmara University, Faculty of Medicine, İstanbul, Türkiye

^e Department of Anesthesiology and Reanimation, Rumeli University, Faculty of Medicine, İstanbul, Türkiye

^f Department of Anesthesiology and Reanimation, İstanbul University-Cerrahpaşa, Faculty of Medicine, İstanbul, Türkiye

ABSTRACT

Aim: Transversus Abdominis Plan (TAP) block is an interfascial plane block, commonly used as an analgesic technique in abdominal surgeries. The aim of this study is to investigate the postoperative analgesic efficacy of bilateral ultrasonography (US) guided TAP block in patients scheduled for laparoscopic sleeve gastrectomy.

Method: In this randomized prospective study; 48 patients, 18-65 years, ASA I-II, morbidly obese (BMI>35), underwent laparoscopic sleeve gastrectomy were included. The patients randomized into two groups: TAP block Group (group TAP) and Control Group (group C). At the end of the operation, bilateral TAP block were performed to 24 patients in Group TAP with a total 40 ml of local solution. 20 ml of local solution was injected into the trocar incision lines of all patients. Patient-controlled analgesia was administered to all patients at a dose of 5 mg/ml tramadol. Tramadol consumption, visual analogue scores (VAS) and the need of rescue analgesia (paracetamol) of the patients at postoperative first 24th hours were recorded.

Results: There is no statistical difference in terms of demographic data. Total tramadol consumption and VAS were significantly higher in the Group C (p<0.01). No complications were found in either group.

Conclusions: US-guided TAP block provides effective analgesia in patients underwent laparoscopic sleeve gastrectomy surgery.

ARTICLE INFO

Article history:

Received 27 May 2023

Revised 4 June 2023

Accepted 15 June 2023

Keywords:

Sleeve gastrectomy

Bariatric surgery

Obesity

Postoperative pain

Transversus abdominis plane block

1. Introduction

The prevalence of obesity is increasing worldwide [1]. Globally, a total of 1.9 billion overweight and 609 million obese adults were estimated to be overweight and obese, nearly 40% of the world's population [2]. Obesity is a se-

rious co-morbidity for patients. Several methods may be used for the treatment of obesity [3]. Since it is minimally invasive, bariatric surgery is one of the most commonly used method among the surgical approaches [4]. When postoperative pain is not adequately controlled, quality of life decreases and respiratory complications develop

* Corresponding author. E-mail address: selcukalver@yahoo.com (S. Alver)
ISSN: 2980-292X / DOI: <https://doi.org/10.20528/cjpm.2023.01.003>

[5]. Perioperative pain management is specific in morbidly obese patients, and a multimodal postoperative pain strategy should be used effectively. Thus, the amount of opioid use decreases [6,7]. In morbidly obese patients, the risk of postoperative complications is high due to increased sedation, hypoventilation and immobilization due to opioid use in the postoperative period [8,9]. Enhanced Recovery after Surgery (ERAS) guidelines recommend minimally opioid using in obese patients who underwent bariatric surgery [10].

Transversus Abdominis Plane (TAP) block was defined by Rafi in 2001 as a local anesthetic injection performed by determining the Petit triangle between the transversus abdominis and internal oblique muscles [11]. TAP block provides analgesia as a part of multimodal pain control regimen. The Ultrasound-guided (US) TAP block is an interfascial plane block of the abdominal wall that provides somatic analgesia. Postoperative pain and opioid requirement decreased significantly in patients who underwent TAP block in other surgical branches [8,12,13].

In this trial; our aim was to investigate the analgesic efficacy of US-guided TAP block in the first 24 hours and the need for additional analgesia in patients with laparoscopic sleeve gastrectomy under general anesthesia.

2. Materials and Methods

After obtaining the approval of the ethics committee of Bezmialem Vakif University Faculty of Medicine (decision no: 71306642/050-01- 04/126); ASA I-II, planned for laparoscopic sleeve gastrectomy surgery, and morbidly obese (BMI>35) patients who were aged between 18-65 years included in the study. Written informed consent was obtained from the participants for the study. Patients with a history of drug allergy, ASA \geq 3, chronic opioid and NSAID use, and infection in the skin area were excluded from the study. Randomization was performed by the closed envelope method.

2.1. Study groups and outcome measures

The patients were randomized into two groups. TAP block was performed before extubation at the end of surgery in Group TAP, the other group was non-intervention Control Group (Group C). The primary outcome of our trial; to compare the pain scores with visual analogue scale (VAS). Our secondary outcome is the use of opioid and rescue analgesic use in the postoperative period.

2.2. Intraoperative management

Routine ASA monitoring was performed in the patients. All treatments were calculated based on corrected body weight. A dose of 2 mg/kg propofol, 0.5-1 μ g/kg remifentanyl, and rocuronium 0.6 mg/kg IV were administered for anesthesia induction. Mechanical ventilation is measured with 6 mL/kg tidal volume and PEEP 8 cmH₂O parameters. During the maintenance of anesthesia, a dose of 8-10 mg/kg/hr propofol, 0.25 μ g/kg/min

remifentanyl IV were administered. A dose of 50 mg ranitidine, 20 mg tenoxicam and 1 g paracetamol IV were administered to patients in all groups.

2.3. Performance of transversus abdominis plane block (TAP)

In the TAP group (n: 24), after the surgical procedure was completed, before extubation, after asepsis was achieved in the supine position, TAP block was performed with a linear US probe (8-12 MHz), 150 mm block needle, with in-plane technique.

The transducer was placed in the middle of the iliac crest and costal border (Fig. 1). External oblique, internal oblique, transversus abdominis muscles and peritoneum were visualized (Fig. 2). 1 ml of saline was given to confirm the plan between the internal oblique muscle and the transversus abdominis muscle.

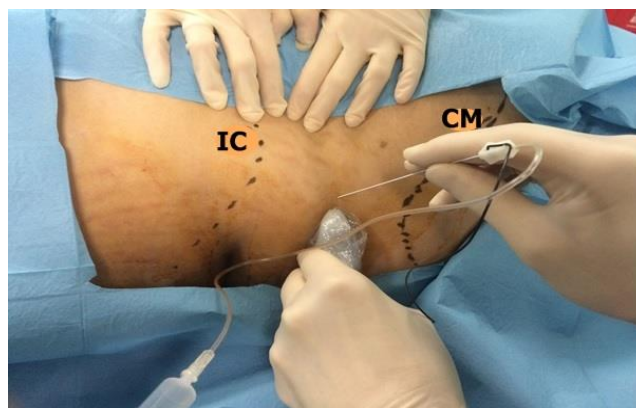


Fig. 1. Probe position and anatomical landmarks.
IC: Iliac crest; CM: Costal margin.

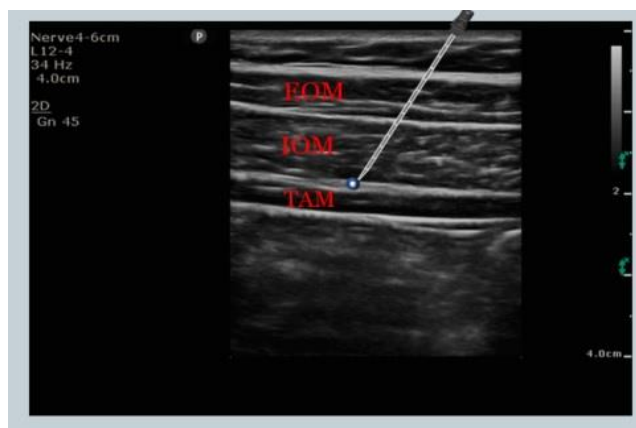

Fig. 2. Sonoanatomy of TAP block.
EOM: External oblique muscle, IOM: internal oblique muscle, TAM: Transversus abdominis muscle.

We prepared 0.5% bupivacaine at a dose of 1.5 mg/kg for block procedure. We diluted 0.5% bupivacaine at lower concentrations with normal saline. We used a mixture of bupivacaine and saline. After confirmation, 40 ml of local anesthetic solution was given bilaterally to the interfascial plane between transversus abdominis and internal oblique muscles.

All patients in the study were infiltrated into the trocar entry sites by the surgical team with 20 ml of local solution. We prepared 0.5% bupivacaine at a dose of 0.5 mg/kg for block procedure. We diluted 0.5% bupivacaine at lower concentrations with normal saline for local infiltration. The block and local solutions were prepared according to the corrected weight of the patients.

2.4. Postoperative analgesia protocol

Postoperative tramadol (5 mg/ml) patient-controlled analgesia (PCA) was administered to the patients; 4cc bolus, lock time 20 min (no infusion). If the VAS was above 4, 1 g paracetamol was used for rescue analgesic purposes.

2.5. Sample size analyses and statistics

The sample size of the study was calculated using the G*Power program (V.3.1.9 Heinrich-Heine- Universitat Dusseldorf, Germany) based on a pilot study with 8 patients in each group. The power analysis was based on VAS scores which was the primary outcome of the study. We considered a reduction in mean pain scores by two points to be clinically meaningful and important. The mean of VAS scores of the TAP group was 3 with SD=2

and, 5 with SD=3 in the control group. Assuming a two-sided type I error of 0.01, along with type II error of 0.10 which eventually brings a power of 0.90(1- β), 21 participants were needed per each group. Considering possible drop-outs, we decided to include at least 24 patients per group.

IBM SPSS Statistics 22 (IBM SPSS, Turkey) program was used for statistical analysis. While evaluating the study data, the conformity of the parameters to the normal distribution was evaluated with the Shapiro Wilks test. While evaluating the study data, in addition to descriptive statistical methods (mean, standard deviation, frequency), Student's t test was used for the comparison of normally distributed parameters between two groups, and Mann Whitney U test was used for the comparison of non-normally distributed parameters between two groups. Fisher's Exact Chi-Square test and Continuity (Yates) Correction were used to compare qualitative data. Significance was evaluated at the $p < 0.05$ level.

3. Results

We used Consolidated Standards of Reporting Trials flow chart for the enrollment of the patients during the trial period (Fig. 3).

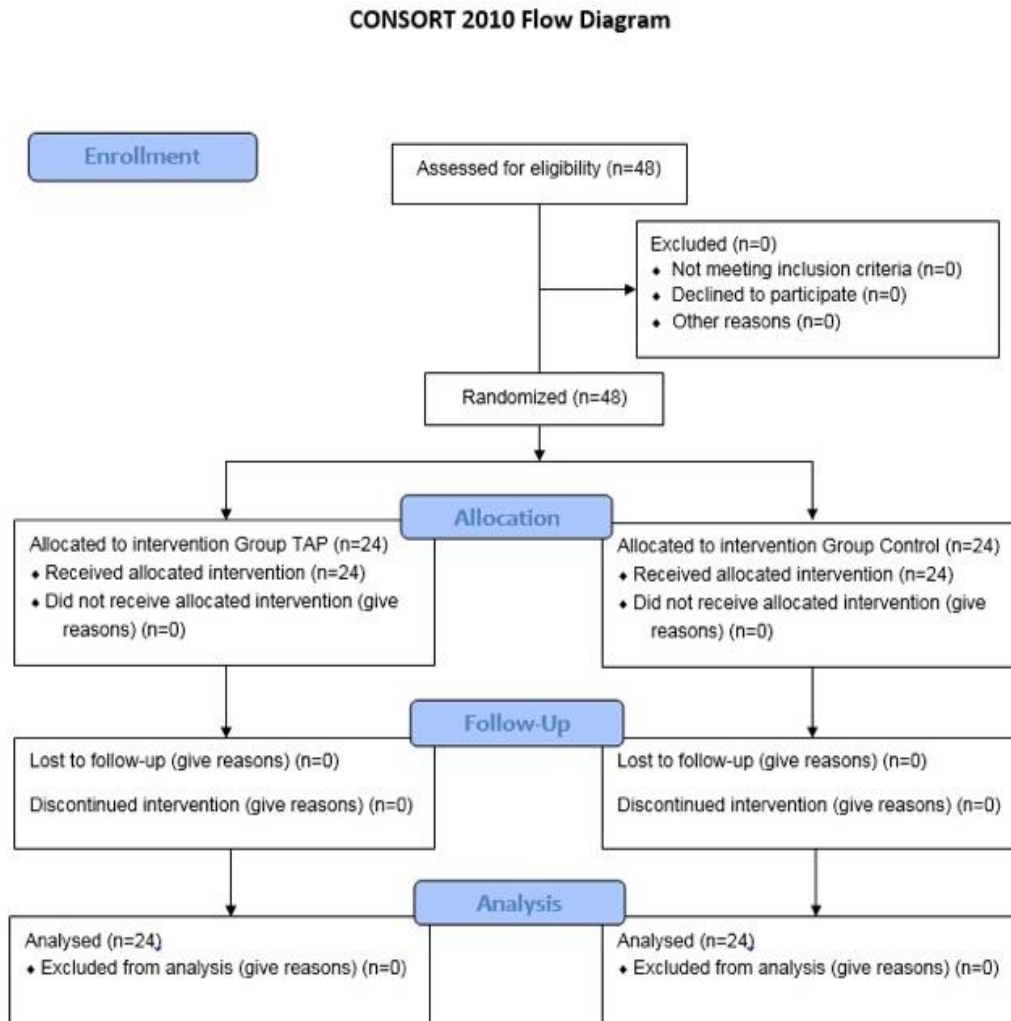


Fig. 3. The process from initial identification of patient files to inclusion is demonstrated.

The study was conducted between May and September 2014 on a total of 48 patients aged 19–64, 16 (33.3%) men and 32 (66.7%) women. The mean age of the cases was 37.54 ± 11.30 years. The participants were randomized into two groups as TAP and groups C ($n = 24$ for each group). There was no statistically significant difference between the groups in terms of age, gender, weight, height, BMI, corrected weight averages, anesthesia duration and surgical time periods ($p > 0.05$) (Table 1).

The VAS-rest and VAS-movement levels of the C group at the 30th minute, 2nd, 6th, 12th and 24th hours were found to be statistically significantly higher than the TAP group ($p < 0.05$). (Table 2). Total tramadol consumption at 30th minute, 2nd, 6th, 12th and 24th hours and paracetamol usage rates at 30th minute, 2nd, and 6th hours in the C group were found to be significantly higher than the TAP group. ($p < 0.05$) (Table 3). There were no complications in either group.

Table 1. Evaluation of the groups in terms of demographic characteristics.

	Group TAP (n: 24)	Group Control (n: 24)	p
Age (years)	36.33 ± 12.07	38.75 ± 10.6	0.465
Weight (kg)	136.25 ± 20.98	137.42 ± 23.01	0.855
Height (cm)	168.54 ± 11.65	164.75 ± 11.14	0.255
BMI (kg/m ²)	48.23 ± 7.18	50.49 ± 6.04	0.243
Adjusted weight (kg)	91.23 ± 13.45	89.59 ± 14.28	0.683
Gender F/M	15/9	17/7	0.759
Anesthesia time (min)	137.67 ± 14.7	141.08 ± 17.46	0.467
Surgery time (min)	98.5 ± 12.76	98.17 ± 17.74	0.941

The data are presented as mean \pm standard deviation or number, kg: kilogram, cm: centimeter, min: minute, BMI: body mass index, Continuity (yates) correction was used for gender, Student t-test was used for other parameters.

Table 2. Evaluation of the groups in terms of VAS-Rest and VAS-Movement.

	Group TAP (n: 24)	Group Control (n: 24)	p
VAS-Rest			
30 min	4.96 ± 0.75	6.58 ± 0.88	0.001**
2nd hour	3.33 ± 0.76	6.13 ± 0.74	0.001**
6th hour	1.75 ± 0.68	4.83 ± 0.56	0.001**
12th hour	1.54 ± 0.51	3.79 ± 0.41	0.001**
24th hour	1 \pm 0	1.58 ± 0.5	0.001**
VAS-Movement			
30 min	5.96 ± 0.75	7.71 ± 0.95	0.001**
2nd hour	4.33 ± 0.76	7.21 ± 0.66	0.001**
6th hour	2.54 ± 0.72	5.79 ± 0.59	0.001**
12th hour	2.46 ± 0.51	5.21 ± 0.72	0.001**
24th hour	1.42 ± 0.50	2.38 ± 0.49	0.001**

The data are presented as mean \pm standard deviation. VAS: Visual analogue scale, Mann Whitney U test used ** $p < 0.01$.

4. Discussion

In our study, we compared the analgesic efficacy of bilateral TAP block + LA infiltration, to LA infiltration alone. According to the results, the pain scores, opioid consumption (tramadol), and the need for rescue analgesia (paracetamol) were significantly lower in the TAP group. Multimodal postoperative pain analgesia management may be used effectively after bariatric surgery.

Table 3. Evaluation of the groups in terms of total tramadol and paracetamol consumption.

	Group TAP (n: 24)	Group Control (n: 24)	p
Tramadol Consumption			
30 min	26.67 ± 9.63	34.38 ± 10.35	0.008**
2nd hour	$95 \pm 25,19$	222.5 ± 40.99	0.001**
6th hour	$175.83 \pm 48,63$	327.5 ± 40.78	0.001**
12th hour	$271.67 \pm 48,6$	426.67 ± 52.97	0.001**
24th hour	$354.17 \pm 48,09$	531.67 ± 58.66	0.001**
Paracetamol Consumption			
30 min	2 (%8,3)	18 (%75)	0.001**
2nd hour	1 (%4,2)	18 (%75)	0.001**
6th hour	0 (%0)	5 (%20,8)	0.049*
12th hour	0 (%0)	0 (%0)	NS
24th hour	0 (%0)	0 (%0)	NS

The data are presented as mean \pm standard deviation or number. NS: Nonsignificant, Continuity (yates) correction and Fisher's Exact Test used * $p < 0.05$, ** $p < 0.01$.

A multimodal analgesia regimen reduces the amount of opioid use in obese patients. The pain control contributes to the rehabilitation of patients [6,7]. Hebbard et al. described the TAP block under guidance of US [14]. It has been used effectively in laparoscopic surgeries, even in pediatric and neonatal patients [15,16]. In studies, the classical blind technique (loss of resistance) method and the US technique were compared [9,17]. It is very difficult to find guide points in morbidly obese patients. In obese patients with TAP block, palpation of the petit triangle is quite difficult. In recent years, regional anesthesia with the US technique provides safe and effective anesthesia in obese patients [12,13]. For these reasons, we preferred the US technique in our study.

Albrecht et al. [18] divided the cases undergoing laparoscopic gastric bypass into two groups and performed bupivacaine to TAP block and trocar inlets in 27 patients, and bupivacaine to only trocar inlets in 30 patients. Both 0–24 and 24–48 in opioid consumption in this study. There was no difference between operating hours and pain scores were similar. In this study, it was argued that TAP block application would be useless in the presence of local anesthetic agent performed to the incision lines. Although local anesthesia infiltration was performed to the surgical incision lines in all patients in our study, a significant difference was observed in pain scores and tramadol consumption amounts between the patients

between 0-24 hours. The different aspect of our study is that the TAP block application was performed immediately after the end of the surgery. Thus, the effectiveness of TAP block was felt more in the early postoperative period. In addition, the use of PCA contributed to the relevance of the study.

Sinha et al. [19] bupivacaine and TAP block were performed to one group and bilateral saline was performed to the other group in 100 patients who were scheduled for laparoscopic bariatric surgery. In the study, a significant decrease was found in the need for analgesics in the TAP block group within the first 6 hour postoperatively. It was determined that the pain scores of the patients were lower in the block group and the sedation values were significantly reduced. In our study, tramadol was consumed less in the TAP block group. Again, resting and mobile VAS were significantly reduced. In addition, placebo was not administered to the group that did not receive TAP block in our study. We did not observe any complications in any of our patients who underwent block. Wasseef et al. [20] studied 35 patients who underwent single-port laparoscopic bariatric surgery. Postoperatively, only iv PCA and hydromorphone were performed to 25 patients, postoperative TAP block was performed to 10 patients, and postoperative iv PCA was given to hydromorphone. Sensory blocks T5-L1 dermatome levels were detected and no difference was observed between the two groups in 24-hour opioid consumption. In our study, dermatomal areas of sensory block were not detected, but a significant decrease was detected in both VAS scores and postoperative analgesia consumption in the TAP group.

Another fascial plane blocks such as oblique subcostal transversus abdominis plane (OSTAP) block, thoracoabdominal nerve block through perichondrial approach (TAPA) block, and erector spinae plane block (ESPB) may be used for abdominal analgesia and postoperative pain control after bariatric surgery [21–25]. OSTAP was modified from the subcostal TAP block by Hebbard et al. [25]. OSTAP has some difficulties such as longer needle and larger volume of LA (50-80 ml) are needed. OSTAP provides analgesia between T6-L1 levels, and it targets anterior cutaneous branches. TAPA block is a novel abdominal interfascial plane block [22,23]. It is performed over and underside of the costal cartilage. It provides effective abdominal analgesia by targeting anterior and lateral cutaneous branches. It was reported that modified TAPA provided effective analgesia in patients underwent sleeve gastrectomy surgery [23]. Erector spinae plane block (ESPB) is a technique that LA is administered deeply to the erector spinae muscle over the transverse process of vertebrae. T9-T10 ESPB provides abdominal analgesia. It was reported that ESPB provided postoperative analgesia after bariatric surgery [24].

This trial has several limitations. We performed 40 ml volume of LA for TAP block. Further studies may be performed with different volumes. As another limitation, we did not evaluate the dermatome levels.

5. Conclusions

In conclusion, US-guided TAP block provides effective analgesia in patients underwent laparoscopic sleeve gastrectomy surgery. It may be used as a part of multimodal analgesia management in obese patients. Further studies with larger sample size are needed to better evaluate the efficacy of TAP block.

Author Contributions

All authors have made significant contributions to the design or data acquisition or analysis and interpretation of data; were involved in the drafting or critical review for important intellectual content; gave final approval of the version to be published.

Acknowledgements

None declared.

Funding

The authors received no financial support for the research, authorship, and/or publication of this manuscript.

Conflict of Interest

The authors declared no potential conflicts of interest with respect to the research, authorship, and/or publication of this manuscript.

Data availability

The datasets created and/or analyzed during the current study are not publicly available, but are available from the corresponding author upon reasonable request.

REFERENCES

1. Niyazioglu M, Dellal F. Bariatrik Cerrahi Endikasyonları, *Türkiye Klinikleri* **2012**;5(2):1-4.
2. Chooi YC, Ding C, Magkos F. The epidemiology of obesity. *Metabolism*. **2019** Mar;92:6-10.
3. Bray GA, Heisel WE, Afshin A, et al. The science of obesity management: an endocrine society scientific statement. *Endocr Rev*. **2018**;39:79–132.
4. Alamuddin N, Bakizada Z, Wadden TA. Management of obesity. *J Clin Oncol*. **2016**;34:4295–305.
5. Chou R, Gordon DB, de Leon-Casasola OA, et al. Management of postoperative pain: a clinical practice guideline from the American Pain Society, the American Society of Regional Anesthesia and Pain Medicine, and the American Society of Anesthesiologists' Committee on Regional Anesthesia, Executive Committee, and Administrative Council. *J Pain*. **2016**;17:131–57.

6. Govindarajan R, Ghosh B, Sathyamoorthy MK, et al. Efficacy of ketorolac in lieu of narcotics in the operative management of laparoscopic surgery for morbid obesity. *Surg Obes Relat Dis.* **2005**;1:530–5.
7. Madan AK, Ternovits CA, Speck KE, et al. Inpatient pain medication requirements after laparoscopic gastric bypass. *Obes Surg.* **2005**;15:778–81.
8. Brolin RE. Gastric bypass. *Surg Clin North Am.* **2001**;81:1077–95.
9. Byrne TK. Complications of surgery for obesity. *Surg Clin North Am.* **2001**;81:1181–93.
10. Thorell A, MacCormick AD, Awad S, et al. Guidelines for perioperative care in bariatric surgery: Enhanced Recovery After Surgery (ERAS) Society recommendations. *World J Surg.* **2016**;40:2065–83.
11. Rafi AN. Abdominal field block: a new approach via the lumbar triangle. *Anaesthesia* **2001**;56:1024–6.
12. Carney J, Finnerty O, Rauf J, et al. Ipsilateral transversus abdominis plane block provides effective analgesia after appendectomy in children: a randomized controlled trial. *Anesth Analg.* **2010**;111:998–1003.
13. Mukhtar K, Singh S. Transversus abdominis plane block for laparoscopic surgery. *Br J Anaesth.* **2009**;102:143–4.
14. Hebbard P, Fujiwara Y, Shibata Y, Royse C. Ultrasound-guided transversus abdominis plane (TAP) block. *Anaesth Intensive Care.* **2007**;35:616–7.
15. Suresh S, Chan V W.S. Ultrasound guided transverses abdominis plane block in infants, children and adolescents: a simple procedural guidance for their performance. *Paediatr Anaesth* **2009**;19:296–9.
16. Fredrickson MJ, Seal P. Ultrasound-guided transversus abdominis plane block for neonatal abdominal surgery. *Anaesth Intensive Care* **2009**;37(3):469e72.
17. McDonnell JG, O'Donnell B, Curley G, Heffernan A, Power C, Laffey JG. The analgesic efficacy of transversus abdominis plane block after abdominal surgery: a prospective randomized controlled trial. *Anesth Analg.* **2007**; 104: 193–7.
18. Albrect E, Kirkham KR, Endersby RVW, Chan VWS, Jackson T, Okrainec A, Penner T, Jin R, Brull R. Ultrasound-Guided Transversus Abdominis Plane Block for Laparoscopic Gastric-Bypass Surgery: *Obes Surg* **2013**; 23: 1309–1314.
19. Sinha A, Jayaraman L, Punhani D. Efficacy of Ultrasound-Guided Transversus Abdominis Plane Block After Laparoscopic Bariatric Surgery: *Obes Surg* **2013**; 23:548–553
20. Wassef M, Lee DY, Levine JL, Ross RE, Guend H, Vandepitte C, Hadzic A, Teixeira J. Feasibility and Analgesic Efficacy of The Transversus Abdominis Plane Block After Single-Port Laparoscopy in Patient Having Bariatric Surgery: *Journal of Pain Research* **2013**;6 837–841.
21. Tsai HC, Yoshida T, Chuang TY, Yang SF, Chang CC, Yao HY, Tai YT, Lin JA, Chen KY. Transversus Abdominis Plane Block: An Updated Review of Anatomy and Techniques. *Biomed Res Int.* **2017**;2017:8284363. doi: 10.1155/2017/8284363. Epub 2017 Oct 31.
22. Güngör H, Ciftci B, Alver S, Gölboyu BE, Ozdenkaya Y, Tulgar S. Modified thoracoabdominal nerve block through perichondrial approach (M-TAPA) vs local infiltration for pain management after laparoscopic cholecystectomy surgery: a randomized study. *J Anesth.* **2023** Apr;37(2):254–260. doi: 10.1007/s00540-022-03158-0. Epub 2022 Dec 28. PMID: 36575362.
23. de Oliveira EJS, De Lima RC, Sakata RK, Freire TT, de Almeida Lima EL, de Oliveira CMB, Moura ECR, da Cunha Leal P. Modified Thoracoabdominal Nerve Block Through the Perichondrial Approach (M-TAPA) in Laparoscopic Sleeve Gastropasty: A Case Series. *Obes Surg.* **2022** Jan;32(1):197–201. doi: 10.1007/s11695-021-05612-6. Epub 2021 Aug 2. PMID: 34339018.
24. Abdelhamid BM, Khaled D, Mansour MA, Hassan MM. Comparison between the ultrasound-guided erector spinae block and the subcostal approach to the transversus abdominis plane block in obese patients undergoing sleeve gastrectomy: a randomized controlled trial. *Minerva Anesthesiol.* **2020** Aug;86(8):816–826. doi: 10.23736/S0375-9393.20.14064-1. Epub 2020 May 22. PMID: 32449336.
25. Hebbard PD, Barrington MJ, Vasey C. Ultrasound-guided continuous oblique subcostal transversus abdominis plane blockade: description of anatomy and clinical technique. *Reg Anesth Pain Med.* **2010** Sep-Oct;35(5):436–41. doi: 10.1097/aap.0b013e3181e66702. PMID: 20830871.